

Subcutaneous Dirofilariasis presenting as a heel swelling: An unusual presentation

Dr. Manish Sirse¹, Dr. Mayur N Hebsur², Dr. Surendra U Kamath³

¹ Senior Resident, Sanjay Gandhi Institute of Trauma and Orthopaedics, Bangalore, Karnataka, India

² Department of Orthopaedics, Siwach Sanjeevani Hospital, Rohtak, Haryana, India

³ Senior Professor & Consultant, Manipal Hospitals, Mangalore, Karnataka, India

Corresponding Author: Dr. Mayur N Hebsur

DOI: <https://doi.org/10.66856/ijor.2026.8.2.8023>

Abstract

Human dirofilariasis is a rare zoonotic infection transmitted by mosquitoes, most commonly caused by *Dirofilaria repens*. It typically presents as subcutaneous nodules, often mimicking benign or inflammatory lesions. We report a case of a 62-year-old man presenting with a painless swelling over the right heel of three months' duration. Ultrasonography suggested a parasitic cyst. The lesion was surgically excised, and histopathological examination confirmed subcutaneous dirofilariasis. The patient was treated with diethylcarbamazine postoperatively and recovered uneventfully. This case highlights the importance of considering parasitic infections in the differential diagnosis of subcutaneous swellings, especially in endemic regions.

Keywords: Human Dirofilariasis, *Dirofilaria repens*, subcutaneous swelling, zoonotic infection, heel lesion

Introduction

Human dirofilariasis is an emerging zoonotic infection, and it typically manifests in humans as pulmonary, ocular, or subcutaneous lesions [1]. Dirofilariasis is caused by filarial nematodes. It is a zoonotic infection which is caused by *D. immitis*, *D. repens*, *D. tenuis* and *D. ursi*. It is transmitted to humans by the *Culex*, *Aedes* or the *Anopheles* mosquitoes, which ingest the blood-containing microfilaria from affected dogs. Human Dirofilariasis is rare. The reported cases of the *Dirofilaria* infection in humans are mainly caused by 2 species, *Dirofilaria immitis* (*D. immitis*) and *Dirofilaria repens*. This mosquito-borne infection occurs in humans because of aberrant inoculation of the microfilaria.

We present a case of subcutaneous filariasis in a 62-year-old man from Southern part of Karnataka, India. Human subcutaneous dirofilariasis is caused by *Dirofilaria repens*, a

parasite in the subcutaneous tissue of dogs, cats, and other canids. It is transmitted by mosquito's endemic to Southern and Eastern Europe and Asia, particularly Sri Lanka, Malaysia, and India [2].

Case Presentation

A 62-year-old man, hailing from South India, presented with swelling at the right heel for the past three months. The swelling was associated with mild pain. There was no associated itching, rash, cough, or abdominal symptoms initially, and then later after 3 months the itching and redness started, as such he had no significant past medical history. On clinical examination, a 3×2 centimetres (cm) sized well-defined firm swelling with no restriction of movements at right ankle and was found over the right Heel. There was no tenderness or local rise in temperature.

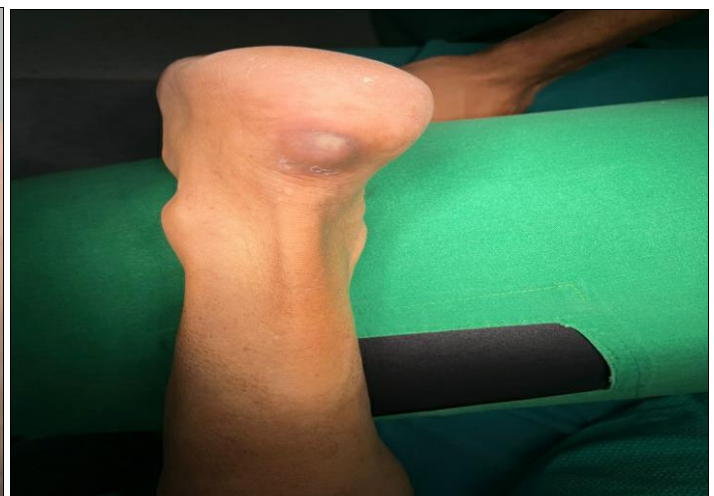
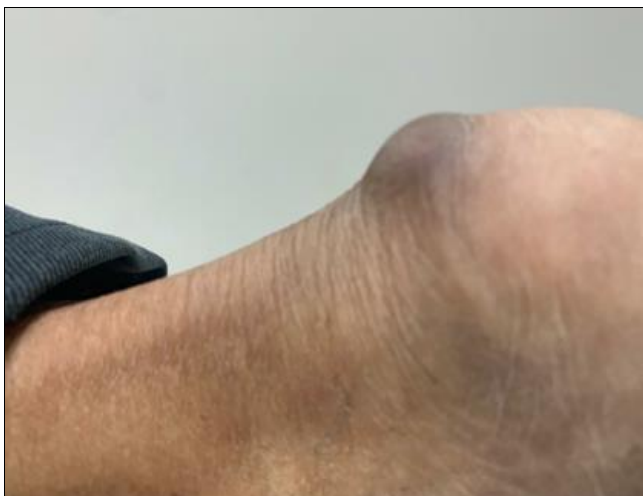

Fig 1-2: Lateral view of the swelling over calcaneal tuberosity and posterior view)

Ultrasonography showed a 13*6*14mm (TR*AP*CC) mm-sized hypoechoic lesion in the subcutaneous plane over the right heel.

Elongated curvilinear double echogenic line lesion with multiple coils noted within the cyst. It does not show any movement- likely dead worm/ parasite.

The wall of the cyst is mildly thick and is measuring 5_6mm in thickness with minimal surrounding edema – like

inflammatory changes. Visualised Achilles tendon appears normal.

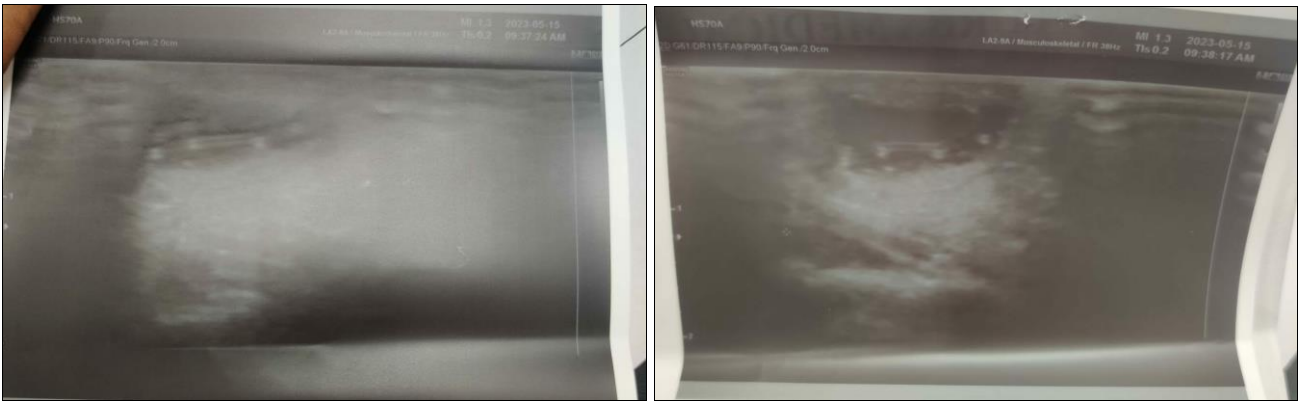

Fig 3-4: Impression was subcutaneous cyst lesion with features likely of parasitic infestation and inflammation

Hemogram showed no eosinophilia and the peripheral blood smear was normal. Serum immunoglobulin (Ig)E level was normal.

The swelling was excised in total under spinal anaesthesia and the specimen was sent for histopathology and microbiological study (Figure 5).

Histopathologic examination of the cyst showed fibro-fatty tissue with a cavity showing parasite having an outer thick multi-layered cuticle showing longitudinal ridges and a muscular layer around the body cavity. This is surrounded by granulomatous inflammation composed of epithelioid histiocytes, multi nucleated giant cells along with granulation tissue, and dense inflammatory infiltrate composed of neutrophils and eosinophils.

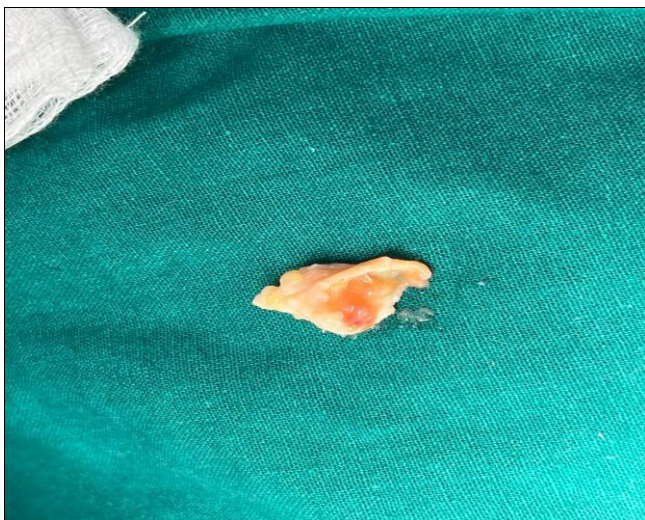Diagnosis was given as Granulomatous inflammation secondary to parasitic infestation, morphology suggestive of subcutaneous dirofilariasis.

Discussion

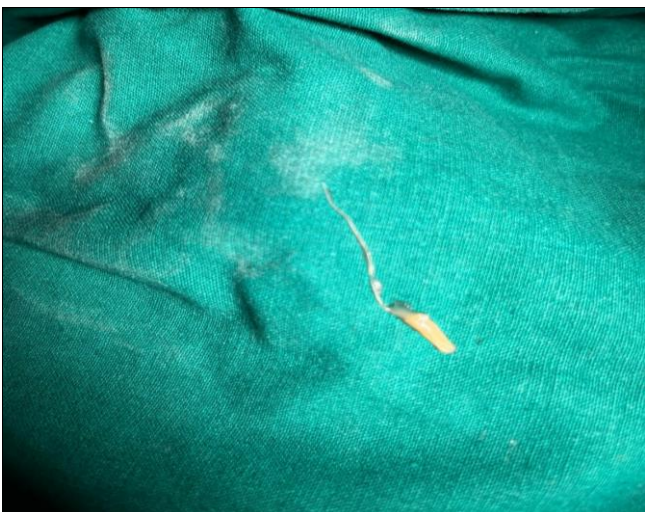Human dirofilariasis is a mosquito-borne zoonotic nematode infection. *Dirofilaria immitis*, *D. repens* and *D. tenuis* are the three most common *Dirofilaria* species causing human infections. Dogs and other wild canids are the natural hosts of these three *Dirofilaria* species. Transmission of the disease to humans occurs by bites of mosquito species like *Aedes*, *Anopheles*, *Culex*, and *Mansonia* [4]. *D. immitis* infection usually causes pulmonary lesions, often producing coin lesions that may or may not be symptomatic [5]. *D. repens* infection typically manifests as subcutaneous or submucosal nodules with adult worms inside [6].

The first-stage larvae circulating in the peripheral bloodstream of the natural hosts are taken up by mosquitos during a blood meal. The larvae mature inside the mosquito and the third-stage larvae are introduced to humans through a bite. Humans are accidental dead-end hosts of the nematode. The organisms mature into adults in humans and rarely cause microfilaremia. Like other filarial nematodes, *D. repens* hosts a bacterial endosymbiont, *Wolbachia* that has been known to manipulate the host immune response in these filarial infections [7, 8].

Subcutaneous nodules caused by *D. repens* can arise anywhere in the body, predominantly affecting the upper body [4]. These usually present as migratory swellings with or without pain. Ocular dirofilariasis can be periorbital, subconjunctival, subtenon or intraocular. The differential diagnosis for subcutaneous dirofilariasis includes infected cysts or abscesses, lipomas, granulomas, and benign or malignant tumors. Peripheral blood eosinophilia and elevated IgE levels are not usually observed. Ultrasonography shows actively motile, tubular structures with parallel echogenic stripes within a cyst [9]. In our case,



The contents of the swelling were pus and one 2 cm long slender tubular worm-like structures (Figure 6).



In our case, the ultrasound of right heel suggested subcutaneous cyst lesion with features likely of parasitic infestation and inflammation (Figure 2).. Histopathologic demonstration of *Dirofilaria* yields the definitive diagnosis. *Dirofilaria* can be identified by a multilayered thick cuticle with longitudinal ridges and well-developed circumferential musculature interrupted by lateral chords^[10]. Histologic examination of the cyst often shows features of chronic inflammation. Microfilaremia is rarely seen in humans and there have been no reported cases of human-to-human transmission.

Surgical excision of the lesion is the definitive treatment for human subcutaneous dirofilariasis. Chemotherapy with ivermectin and diethylcarbamazine can be advised. Avoidance of mosquito bites is the best method to prevent dirofilariasis. Eradication of *Dirofilaria* infection in dogs with combination therapy of ivermectin and doxycycline can be implemented to prevent potential public health issues^[11]. Climate changes could be contributing to the increase in the incidence of similar zoonotic infections as such factors can affect mosquito breeding and disease transmission. An increase in temperature can shorten the lifecycle duration and generation time of various vector species, suitable for the potential transmission of disease-causing pathogens^[12]. Changing climate can impact the land use patterns, which in turn can affect the habitat distribution of vector species promoting disease spread to newer areas and larger populations.

References

1. Simón F, Siles-Lucas M, Morchón R, González-Miguel J, Mellado I, Carretón E, *et al.* Human and animal dirofilariasis: the emergence of a zoonotic mosaic. *Clinical Microbiology Reviews*,2012;25(3):507–544. <https://doi.org/10.1128/CMR.00012-12>
2. Sabu L, Devada K, Subramanian H. Dirofilariosis in dogs and humans in Kerala. *Indian Journal of Medical Research*,2005;121:691–693.
3. Pampiglione S, Rivasi F. Human dirofilariasis due to *Dirofilaria* (*Nochtiella*) *repens*: an update of world literature from 1995 to 2000. *Parassitologia*,2000;42:231–254.
4. Joseph E, Matthai A, Abraham LK, Thomas S. Subcutaneous human dirofilariasis. *Journal of Parasitic Diseases*,2011;35:140–143. <https://doi.org/10.1007/s12639-011-0039-2>
5. Saha BK, Bonnier A, Chong WH, Chieng H, Austin A, Hu K, *et al.* Human pulmonary dirofilariasis: a review for the clinicians. *American Journal of Medical Sciences*,2022;363:11–17. <https://doi.org/10.1016/j.amjms.2021.07.017>
6. Simón F, Diosdado A, Siles-Lucas M, Kartashev V, González-Miguel J. Human dirofilariosis in the 21st century: a scoping review of clinical cases reported in the literature. *Transboundary and Emerging Diseases*,2022;69:2424–2439. <https://doi.org/10.1111/tbed.14210>
7. Grandi G, Morchon R, Kramer L, Kartashev V, Simon F. Wolbachia in *Dirofilaria repens*, an agent causing human subcutaneous dirofilariasis. *Journal of Parasitology*,2008;94:1421–1423. <https://doi.org/10.1645/GE-1575.1>
8. Genchi C, Kramer LH, Sasser D, Bandi C. Wolbachia and its implications for the immunopathology of filariasis. *Endocrine, Metabolic and Immune Disorders Drug Targets*,2012;12:53–56. <https://doi.org/10.2174/187153012799279108>
9. Singh T, Sandhu G, Singla V. Filarial dance sign in breast lump. *BMJ Case Reports*, 2019, 12. <https://doi.org/10.1136/bcr-2019-229956>
10. Gutierrez Y. Diagnostic features of zoonotic filariae in tissue sections. *Human Pathology*,1984;15:514–525. [https://doi.org/10.1016/S0046-8177\(84\)80004-0](https://doi.org/10.1016/S0046-8177(84)80004-0)
11. Bazzocchi C, Mortarino M, Grandi G, *et al.* Combined ivermectin and doxycycline treatment has microfilaricidal and adulticidal activity against *Dirofilaria immitis* in experimentally infected dogs. *International Journal for Parasitology*,2008;38:1401–1410. <https://doi.org/10.1016/j.ijpara.2008.03.002>
12. Medlock JM, Leach SA. Effect of climate change on vector-borne disease risk in the UK. *Lancet Infectious Diseases*,2015;15:721–730. [https://doi.org/10.1016/S1473-3099\(15\)70091-5](https://doi.org/10.1016/S1473-3099(15)70091-5)